



Acute Type an Aortic Dissection during Pregnancy treated Surgically with Maternal and Fetal Survival: Case Report and Review of the Literature

Ben Jmaà H¹, Hamza E¹, Gueldich M¹, Mhiri F¹, Jawadi W², Dammak A¹, Barkallah G², Abid M³, Derbel M³ and Frikha I¹

¹Department of Thoracic and Cardiovascular Surgery, Habib Bourguiba Hospital, Sfax, Tunisia

²Department of Anesthesiology, Habib Bourguiba Hospital, Sfax, Tunisia

³Department of Obstetrics and Gynecology, Hedi Chaker Hospital, Sfax, Tunisia

*Corresponding author: Ben Jmaà H, Department of Thoracic and Cardiovascular Surgery, Habib Bourguiba Hospital, Sfax, Tunisia; Tel: +0021696704740; E-mail: [helabenjmaa2015 \(at\) gmail \(dot\) com](mailto:helabenjmaa2015@gmail.com)

Abstract

Spontaneous aortic dissection in pregnancy is rare and life-threatening for both the mother and the fetus. Early diagnosis and optimal treatment are crucial. We describe the case of a 39-year-old pregnant woman who was transferred to our Centre at 36 weeks of gestation with serious chest pain radiating to her back and vomiting. Ultrasonography revealed dilatation of the aortic root and ascending aorta, severe aortic regurgitation, and moderate concentric left ventricular hypertrophy. Computed tomography confirmed a type a aortic dissection based on the Stanford classification. She was treated by caesarean section prior to open repair of acute type a dissection with Bentall technique. The postoperative course was favourable, and both mother and baby were discharged from hospital with good health.

Keywords: Aortic dissection; Pregnancy; Diagnosis; Multidisciplinary; Surgery; Cesarean

Introduction

Aortic dissection in pregnancy is rare but severe condition to both mother and baby, which occurs most commonly in the third trimester, and is often secondary to genetic cardiovascular problems, such as Marfan syndrome, Turner syndrome, Ehlers-Danlos syndrome, chronic hypertension, or other congenital heart diseases [1]. Pregnancy itself has been associated with an increased risk of aortic dissection [2] because of increasing cardiac output as well as blood volume or hormonal changes. We describe the case of a patient without Marfan syndrome who suffered from the Stanford type A aortic dissection in the third trimester of pregnancy, and who underwent successful surgery.

Case Report

A 39-year-old Tunisian woman without medical disease, was in her 36th week of gestation. She had previously completed two pregnancies. She visited the emergency department with severe chest pain radiating to the back with vomiting since 2 days, and had gradually increased in level despite the patient taking oral pain relief. Clinical examination reveals that vital signs were stable. Blood pressure was 150/90 mm Hg and the uterine fundus was palpable above umbilicus and no uterine contraction.

Heart rate was 85 beats; respiratory rate was 20 breaths per minute; and oxygen saturation was 96%. Cardiovascular examination revealed a diastolic murmur in the aortic space. Chest radiography revealed a mediastinum enlargement (Figure 1). Electrocardiography showed sinus rhythm without ST wave changes. Laboratory tests showed that serum creatinine was 80

Received date: 06 September 2020; **Accepted date:** 13 September 2020; **Published date:** 18 September 2020

Citation: Ben Jmaà H, Hamza E, Gueldich M, Mhiri F, Jawadi W, Dammak A, et al (2020). Acute Type an Aortic Dissection during Pregnancy treated Surgically with Maternal and Fetal Survival: Case Report and Review of the Literature. SunText Rev Surg 1(1): 103.

DOI: <https://doi.org/10.51737/2766-4767.2020.003>

Copyright: © 2020 Ben Jmaà H, et al. This is an open-access article distributed under the terms of the Creative Commons Attribution License, which permits unrestricted use, distribution, and reproduction in any medium, provided the original author and source are credited.

$\mu\text{mol/l}$. The levels of cardiac enzymes (including troponin I) were not increased. Myocardial infarction was excluded on the basis of the ECG and cardiac enzymes results. The fetal heart rate was approximately 126 beats per minute. Fetal ultrasonography showed a viable infant with appropriate gestational age. A transthoracic echocardiogram showed dilatation of the aortic root and ascending aorta, severe aortic regurgitation, and moderate concentric left ventricular hypertrophy. An emergent chest computed tomography angiography (CTA) scan was performed to confirm the findings and to assess the extension. It revealed type A aortic dissection extending to the iliac arteries (Figures 2 and 3). She was transferred to the intensive care unit, and blood pressure was controlled with the use of sodium nitroprusside.

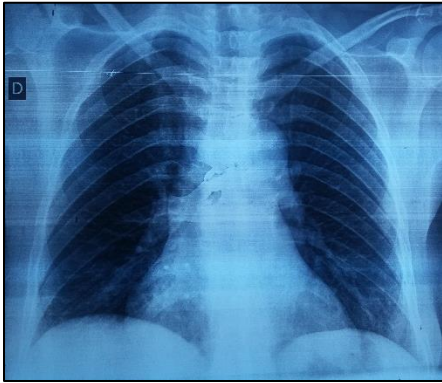
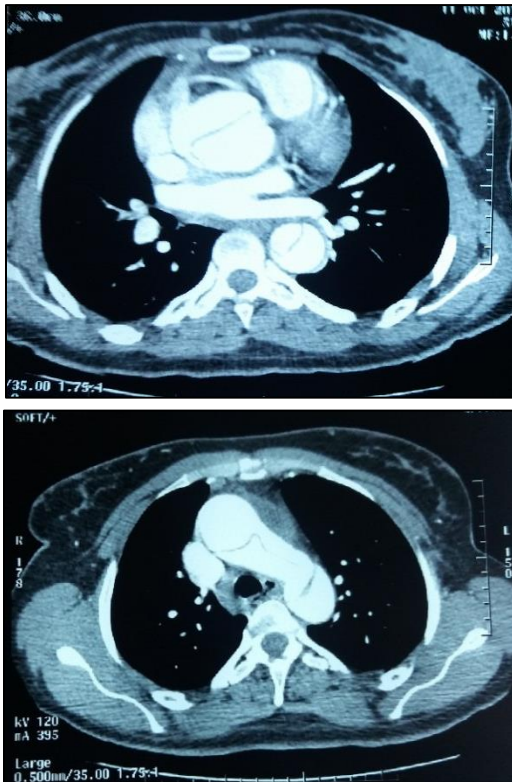


Figure 1: Mediastinum enlargement.



Figures 2 and 3: CT scan showing a dissection of the ascending aorta extending into the arch and the descending thoracic aorta.

With emergent multidisciplinary consultation, including consultation with cardiovascular surgeons, anaesthesiologists, intensivists, obstetricians, and neonatologists, we decided to perform caesarean section prior to the aortic dissection repair. In addition, we used corticosteroid therapy to reduce the risk of perinatal mortality and morbidity. Emergent delivery of the infant by cesarean via a horizontal incision was performed by cesarean under general anesthesia. A female infant was delivered, and weighed was 3200 grammes. The baby was immediately transferred to the neonatal care unit for observation. Abdominal drainage was also performed to control postoperative bleeding. Then, immediately after cesarean, the mother underwent surgery under cardiopulmonary bypass between the femoral artery and the atrium and the vena cava via full sternotomy. Aortotomy revealed dissection from the aortic root, with the intimal tear being located in the ascending aorta. We performed replacement of the aortic valve, the ascending aorta, and reimplantation of the coronary arteries with the Bentall technique (Figures 4-6). After, drainage tubes were inserted into the mediastinum and bilateral pleura. The postoperative course was stable. Both mother and baby were discharged smoothly after treatment.

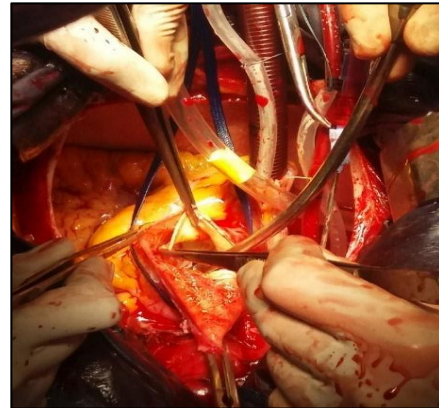


Figure 4: Intra-operative view showing the intimal tear after aortotomy.

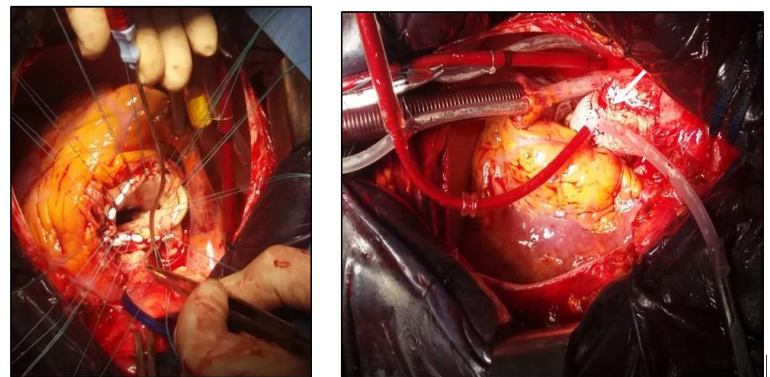


Figure 5 and 6: Intra-operative views showing the replacement of the aortic valve and the ascending aorta by a prosthesis.

Discussion

Acute aortic dissection in pregnancy is a rare, but severe and life-threatening condition most often associated with Marfan syndrome, Ehlers-Danlos syndrome, bicuspid aortic valve, or trauma [3]. But also, the effect of hormones such as estrogen and progesterone which increase the fragility of normal vascular structures and the aortic wall stress, heart rate, cardiac output and increased blood volume during pregnancy, predispose pregnant patients to aortic dilatation with a propensity for dissection [4]. Gestational hypertension (preeclampsia) may also predispose pregnant patients to aortic dissection [5,6]. These changes most commonly occur in the third trimester and postpartum period [5]. In our case, the patient had no evidence of connective tissue disorder or bicuspid valve and blood pressure was normal.

A previous study reported that the overall incidence of acute aortic dissection was approximately 0.4 cases per 100,000 women aged between 15 and 45 years [7]. Anatomically, aortic dissection is divided into two types (A and B) by the Stanford classification. Type A involves the ascending aorta while type B does not. In pregnancy, type A aortic dissection is more common than type B [8]. Without treatment, the mortality rate is high. It is usually presented with severe chest pain or back pain [9]. Sometimes, symptoms may be atypical, and the diagnosis may be delayed. Early diagnosis is very important in the management of acute aortic dissection in the gestational period. Chest X-ray is not widely used for chest pain evaluation in pregnant women. Although the fetal radiation dose is low, a wide mediastinum is only seen in 37% of cases with type A dissection [10].

Trans-thoracic echocardiography is commonly performed as initial imaging modality in women with chest pain during pregnancy. It reduces the risk of radiation exposure. Transesophageal echocardiography, when immediately available, is a reasonable alternative tool for patients with probability of aortic dissection during pregnancy. Also, it provides functional assessments of the heart and it can detect pericardial effusion. It is the recommended diagnostic tool for unstable patients with suspected aortic dissection. However, it cannot assess the extension into the abdominal aorta or the involvement of its branches. However, it needs the experience of doctors. CT scan can provide valuable information for the surgical planning of treatment, even though radiation exposure cannot be avoided. It has almost 100% sensitivity and 98–99% specificity for the diagnosis of aortic dissection [11]. It demonstrates anatomical details highly valuable in surgical preparation.

Magnetic resonance imaging has sensitivities and specificities equivalent to or exceeding that of CT scan and transesophageal echocardiography [12]. It can provide information concerning branch artery involvement, aortic valve pathology and left ventricular dysfunction without exposing the patient to ionised-

radiation [11]. Other case reports have documented successful combined emergent Cesarean section followed immediately by repair of type A dissection [13,14]. The treatment of aortic dissection during pregnancy is a challenge for clinicians. It is based on gestational age, fetal viability, and type of dissection [15]. If the fetus is more than 32 weeks, immediate delivery by cesarean is indicated. If the fetus age is less than 28 weeks, emergent mother surgery without delivery is indicated. In this case, the potential risks of maternal cardiopulmonary bypass on the fetus are large. Between 28 and 32 weeks, physicians should consider the risks to the mother and fetus [2].

In a recent literature review of 150 pregnant patients who underwent cardiac surgery with cardiopulmonary bypass, the fetoneonatal mortality was 18.6% [16]. That's why pulsatile perfusion during CPB may be preferred, because it enhances placental perfusion [17]. In the current case, the patient was managed by cesarean section (more than 34 weeks of gestation) and surgical repair under cardiopulmonary bypass and moderate hypothermia (type A aortic dissection) simultaneously. When cesarean delivery is immediately followed by cardiovascular procedures under cardiopulmonary bypass, the increased bleeding from the abdominal and uterine wounds and placental site should be taken into consideration, and measures should be taken to prevent postpartum hemorrhage [18]. Some authors recommend prophylactic hysterectomy to decrease the risk of postpartum hemorrhage [19].

For the patients with Type B aortic dissection, conservative medical treatment is usually recommended in the absence of rupture or malperfusion [20]. Complications of Type B dissections require immediate surgical intervention as per acute Type A dissections. Genetic testing is reasonable for those without known risk factors for aortic dissection.

Conclusion

Chest pain and upper abdominal pain in the pregnant women, should be always kept in mind to consider the urgent and life-threatening but curable diseases mainly myocardial infarction, pulmonary embolism, or aortic dissection until proven otherwise. We insist to the importance of awareness of this rare medical condition and prompt diagnosis of aortic dissection, in any pregnant woman who presents with unexplained pain, because the diagnosis is often overlooked, with misdiagnosis occurring in 85% of patients presenting with this severe disease. Good coordination between specialists is required to achieve efficiency and surgical success.

References

1. Easo J, Horst M, Schmuck B, Thomas RP, Saupe S, Book M, et al. Retrograde type a dissection in a 24th gestational week pregnant patient e the importance of interdisciplinary

- interaction to a successful outcome. *J Cardiothorac Surg.* 2018; 13: 36.
2. Zeebregts CJ, Schepens MA, Hameeteman TM, Morshuis WJ, Brutel de la Riviere A. Acute aortic dissection complicating pregnancy. *Ann Thorac Surg.* 1997; 64: 1345-1348.
 3. Immer FF, Bansi AG, Immer-Bansi AS, McDougall J, Zehr KJ, Schaff HV, et al. Aortic dissection in pregnancy: analysis of risk factors and outcome. *Ann Thorac Surg.* 2003; 76: 309-314.
 4. Yuan SM. Postpartum aortic dissection. *Taiwan J Obstet Gynecol.* 2013; 52: 318-322.
 5. Khan IA, Nair CK. Clinical, diagnostic, and management perspectives of aortic dissection. *Chest.* 2002; 122: 311-328.
 6. Goland S, Elkayam U. Cardiovascular problems in pregnant women with Marfan syndrome. *Circulation.* 2009; 119: 619-236.
 7. Thalmann M, Sodeck GH, Domanovits H, Grassberger M, Loewe C, Grimm M, et al. Acute type A aortic dissection and pregnancy: a population-based study. *Eur J Cardiothorac Surg.* 2011; 39: 159-163.
 8. Rajagopalan S, Nwazota N, Chandrasekhar S. Outcomes in pregnant women with acute aortic dissections: a review of the literature from 2003 to 2013. *Int J Obstet Anesth.* 2014; 23: 348-356.
 9. Pape LA, Awais M, Woznicki EM, Suzuki T, Trimarchi S, Evangelista A, et al. Presentation, diagnosis, and outcomes of acute aortic dissection: 17-year trends from the International Registry of Acute Aortic Dissection. *J Am Coll Cardiol.* 2015; 66: 350-358.
 10. Colletti PM, Lee KH, Elkayam U. Cardiovascular imaging of the pregnant patient. *AJR Am J Roentgenol.* 2013; 200: 515-521.
 11. Shiga T, Wajima Z, Apfel CC, Inoue T, Ohe Y. Diagnostic accuracy of transesophageal echocardiography, helical computed tomography, and magnetic resonance imaging for suspected thoracic aortic dissection: systematic review and meta-analysis. *Arch Intern Med.* 2006; 166: 1350-1356.
 12. Hiratzka LF, Bakris GL, Beckman JA, Bersin RM, Carr VF, Casey Jr DE, et al. ACCF/AHA/AATS/ACR/ASA/SCA/SCAI/SIR/STS/SVM guidelines for the diagnosis and management of patients with thoracic aortic disease. *J Am Coll Cardiol.* 2010; 76: 43-86.
 13. Lichtman AD. Acute aortic dissection in pregnancy: Cesarean section prior to repair of acute type A dissection. *J Anesth Clin Res.* 2011; 2: 8.
 14. Jovic TH, Aboelmagd T, Ramalingham G. Type A aortic dissection in pregnancy: Two operations yielding five healthy patients. *Aorta.* 2014; 2: 113-115.
 15. Tien TQ, Bang HT. Surgical treatment of acute aortic dissection Stanford type A in the third trimester of pregnancy: A case report. *Case Rep Women's Health.* 2020; 25: 00163.
 16. Yuan SM. Indications for cardiopulmonary bypass during pregnancy and impact on fetal outcomes. *Geburtshilfe Frauenheilkd.* 2014; 74: 55-62.
 17. John AS, Gurley F, Scharf HV. Cardiopulmonary bypass during pregnancy. *Ann Thorac Surg.* 2011; 91: 1191-1196.
 18. Johnston C, Schroeder F, Fletcher SN, Bigham C, Wendler R. Type A aortic dissection in pregnancy. *Int J Obstet Anesth.* 2012; 21: 75-79.
 19. Funakoshi Y, Kato M, Kuratani T, Shigemura N, Kaneko M. Successful treatment of massive pulmonary embolism in the 38th week of pregnancy. *Ann Thorac Surg.* 2004; 77: 694-695.
 20. Rutherford RB, Nolte JE. Aortic and other arterial dissections associated with pregnancy. *Semin Vasc Surg.* 1995; 8: 299-305.