



Novel and Rare Vascular Pathology in the Covid-19 Era: Compartment Syndrome Secondary to Severe Respiratory Failure in Patient with Interstitial Pneumonia

Weimer LE^{1,*}, Cattari G², Binelli A¹, Fanales-Belasio E³, Piras S² and Sensi F⁴

¹National Center for Global Health, Istituto Superiore di Sanita, Rome, Italy

²Reperto COVID, Ospedale Marino-Alghero, ASSL Sassari, ATS Sardegna, Italy

³Department of Infectious Diseases, DMI, Istituto Superiore di Sanità, Rome, Italy

⁴Direzione ASSL Sassari, ATS Sardegna, Italy

*Corresponding author: Weimer LE, National Center for Global Health, Istituto Superiore di Sanita, Rome, Italy; E-mail: lilianaelenaweimer@gmail.com

Abstract

In the emerging 21st century, a devastating new coronavirus, has been identified as the causative agent of acute and atypical cases of pneumonia in the city of Wuhan, China. It is a type of highly pathogenic human coronavirus (HCoV) that causes zoonotic diseases and poses a major threat to public health. Acute respiratory distress syndrome and multiple-organ failure occurred rapidly, resulting in death within a short time. Cytokine storm is considered to be one of the major causes of multiple-organ failure. It plays an important role in the process of disease aggravation. With the expanding domain of presentations in COVID-19 patients, the full range of manifestations is yet to unfold. As the pandemic of COVID-19 keeps unfolding, several atypical manifestations of this viral infection have surfaced up. Actually SARS-CoV-2, reveals a novel and rare disorder characterized by endothelial dysfunction and extravasation of fluid from the vascular space to the interstitial space leading to shock, hemoconcentration, hypoalbuminemia, and subsequent organ failure. This novel vascular pathology characterized by extensive capillary, arteriolar and venular thrombosis leading to clinic-pathological manifestations with unusual features, such as early-onset chest pain, pulmonary infarction, and pulmonary and systemic thromboembolism. We report a Rare Case Report of Compartment Syndrome in the right leg Secondary to Severe Respiratory Failure in an Italian patient with Interstitial Pneumonia caused by Sars-Cov-2.

Keywords: Vascular pathology; Compartment syndrome; Sars-Cov-2; Interstitial pneumonia; Early diagnosis

Background

In the emerging 21st century, a devastating new coronavirus, has been identified as the causative agent of acute and atypical cases of pneumonia in the city of Wuhan, China. It is a type of highly pathogenic infection Human Coronavirus (HCoV) that causes and poses a major threat to zoonotic diseases Public Health. Acute respiratory distress syndrome and multiorgan failure have occurred quickly, leading to death within a short period of time. A cytokine storm is one of the main causes of multiple organ failure. It plays an important role in the process of disease aggravation.

[1]. with the expanding domain of presentations in COVID-19 patients, the full range of manifestations is yet to unfold. As the pandemic of COVID-19 keeps unfolding, several atypical manifestations of this viral infection have surfaced up.

Actually SARS-CoV-2, reveals a novel and rare disorder characterized by endothelial dysfunction and extravasation of fluid from the vascular space to the interstitial space leading to shock, hemoconcentration, hypoalbuminemia, and subsequent organ failure. This novel vascular pathology characterized by extensive capillary, arteriolar and venular thrombosis leading to clinic-pathological manifestations with unusual features, such as

Received date: 02 July 2021; Accepted date: 05 July 2021; Published date: 07 July 2021

Citation Weimer LE, Cattari G, Binelli A, Fanales-Belasio E, Piras S, Sensi F (2021). Novel and Rare Vascular Pathology in the Covid-19 Era: Compartment Syndrome Secondary to Severe Respiratory Failure in Patient with Interstitial Pneumonia. SunText Rev Virol 2(1): 119.

DOI: <https://doi.org/10.51737/2766-5003.2021.019>

Copyright: © 2021 Weimer LE, et al., This is an open-access article distributed under the terms of the Creative Commons Attribution License, which permits unrestricted use, distribution, and reproduction in any medium, provided the original author and source are credited.

early-onset chest pain, pulmonary infarction, and pulmonary and systemic thromboembolism [2].

We report a Rare Case Report of Compartment Syndrome in the right leg Secondary to Severe Respiratory Failure in an Italian patient with Interstitial Pneumonia caused by Sars-Cov-2.

Description

Our 68-year-old Italian patient, developed a fever of 39.1°C, asthenia, myalgia, advanced dyspnea, non-productive cough, seizure, and headache, on April 5, 2021. At Covid Alghero Hospital, Sardina immediately after the CT scan (CT) of her chest showed multiple, bilateral vitreous opacities located in both the subdural and basal spaces (particularly on the right) and an extended left spontaneous pneumothorax with partial lung collapse. Nasal swab samples were collected for the detection of severe acute respiratory syndrome coronavirus 2 (SARS-CoV-2) DNA. The swab samples were tested by real-time reverse transcriptase-polymerase chain reaction. A positive result was received hours later on April 6, 2021.

Our patient was diagnosed with COVID-19 and received Remdesivir 200 mg IV, PPI (pantoprazole 40 mg), antibiotic (Meropenem 2g x 3), diuretic (furosemide 20 mg 1f), steroid (dexamethasone 6 mg), antiarrhythmic (amiodarone (200 mg 1 cp), blood transfusions; O₂ treatment of three intravenous methylprednisolone. Doses of 200 mg. Tocilizumab was given in a single IV. 400 mg dose Prophylactic enoxaparin (8000 x 2) has been prescribed (thrombotic events were not presented).

The patient had a history of drug-compatible arterial hypertension, obesity (BMI 36), paroxysmal atrial fibrillation, obstructive sleep apnea, hypercholesterolemia and multifactorial anemia. Response to treatment was refractory. On April 15, 2021, our patient had a hematoma in the groin area of the right leg in the absence of other symptoms. Hemoglobin in reduction. Prophylaxis with Enoxaparin was suspended (Figure 1).

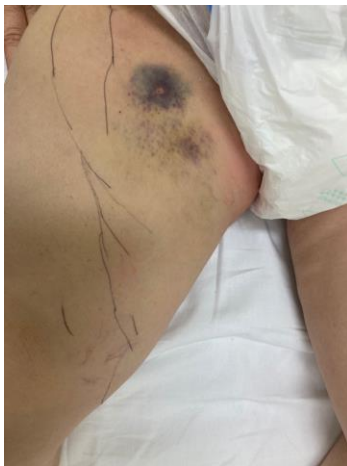

Figure 1: Prophylaxis with enoxaparin has been suspended.

On April 16, 2021, a clinical examination revealed a sensory deficit (decreased sensitivity to touch compared to the opposite limb) with a right knee flexor deficit, and the popliteal pulse imperceptible. Computed tomography scanning and angiography revealed a bulky formation with a mixed, often low-density type appearance of the right sartorius muscle, corresponding to gross myeloma at different stages of regulation, in the dominant stage of impingement, with an image of hyperregression Density, from recent bleeding, is approximately 25 x 6.5 x 8.8 cm. The hematoma extends in the course of the abdominal muscles, from the apex of the Scarpa triangle, along its entire course over the adductor canal to the lower middle third of the thigh.

The popliteal, tibial and tibial arteries show a progressive decrease in filamentous caliber; Great maintenance of the foot vessels. On 17 April 2021, computed tomography and inferior angiography showed an increase in hematoma volume and hyperdense areas in the context of hematopoiesis but without significant spillage of contrast medium at different stages of acquisition (Figure 2).

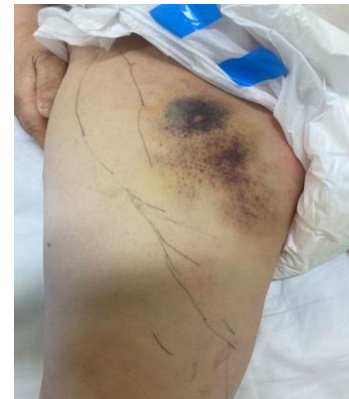

Figure 2: Orthopedic and Vascular consultation has shown no indication for surgical treatment.

An orthopedic and vascular consultation showed no indication for surgical treatment, as no active bleeding was detected. Temporary suspension of Enoxaparin, monitoring of hemoglobin values and transfusions.

Elastic compression therapy using anticoagulant stockings. After treatment, our patient showed progressive clinical stability. A blood test showed a total white cell count (WCC) of 11.5, a neutrophil count of 9.9 and a lymphocyte count of 0.6. His lymphocyte neutrophil ratio (NLR) was 16.5 compared to an expected value <2 for his age group. The C-reactive protein was also significantly increased (132 mg/l compared to the expected less than 5 mg/l) upon introduction. On May 22, 2021, a computerized tomography (CT) scan of her chest revealed complete resolution of bilateral areas of variable density ground glass after treatment and improved arterial blood analysis (Figure 3).

After seven days the vascular disease was resolved. Fortunately, on May 23, 2021, her nasopharyngeal swab samples were negative and after extensive medical treatment in a computerized

tomography (CT) scan in the hospital her chest was maintained with complete accuracy.

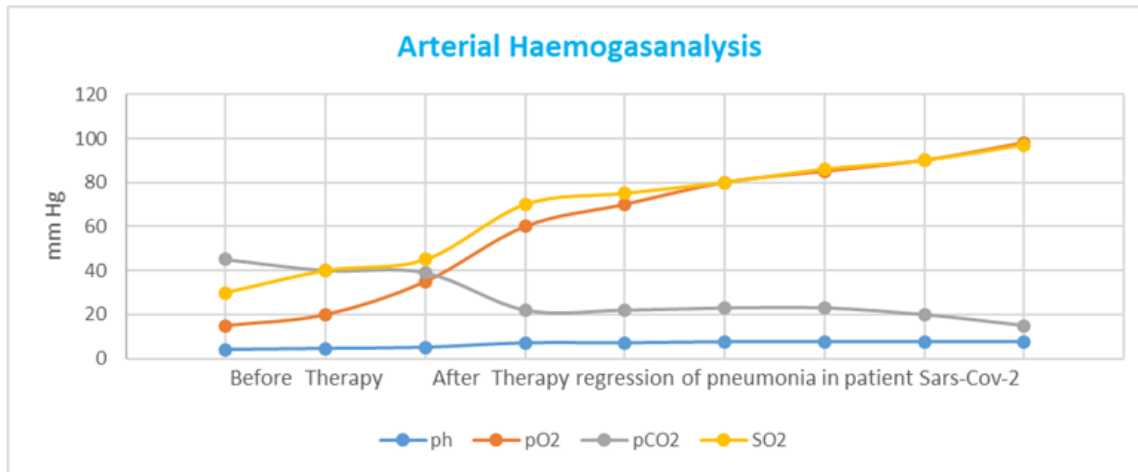


Figure 3: Arterial Haemogasanalysis. Note: Before Tocilizumab and Remdesivir Therapy and After Therapy regression of pneumonia in patient with Sars-Cov-2 and Vascular Pathology.

Discussion

COVID-19 infection has affected patients globally, with infection rates rising in India, Brazil and Europe. The disease has affected patients of all age groups; However, heterogeneity was observed in the outcome of COVID-19 infection associated with comorbidities, ethnic differences, and individual characteristics such as smoking [3].

Cumulative evidence indicates that novel coronavirus, apart from its primary respiratory confinement, may also invade vascular endothelial cells in many systems including the brain, heart, lung and kidney microvasculature, resulting in modulation of multiple visceral perfusion indices.

Under normal conditions, normal parenchymal oxygenation is maintained by three sources: the alveoli and the double supply of oxygen from the circulation of the pulmonary and bronchial arteries. These three components are disrupted in COVID-19 pneumonia, with acute viral alveolitis and concomitant immunocoagulant obstruction of the pulmonary and bronchial circulation [4]. Partial rupture can have two main consequences: systemic embolization of thromboembolism of the pulmonary vein region immune thrombosis and rupture of the vesicular-capillary septum with systemic access of refractory viral substances, leading to catastrophic systemic thrombosis [5].

The SARS-CoV-2-infection-related endotheliitis could explain the systemic impaired microcirculatory function in different vascular beds. In the brain, this endotheliitis seems to induce increased permeability of the blood-brain barrier, leading to a brain edema. Our patient present a rare and novel vasculopathy

characterized by a Compartment Syndrome in the right leg Secondary to Severe Respiratory Failure and Interstitial Pneumonia caused by Sars-Cov-2. Comparative study between various coronavirus reveals similarities in entry and pathogenesis of SARS-CoV-2 along with SARS and MERS in various aspects of multi organ involvement and systematic vasculitis along with similarities in immune-pathogenesis. Dynamic innate and adaptive immune response can augment SARS-CoV2 mediated epithelial and endothelial injury [6]. Non-structural viral particles of SARS-COV2 can hinder heme synthesis of Hb, inducing autoimmune intra vascular hemolysis, hypoxia and inflammatory stress mediated endothelitis and coagulopathy. Array of cardiological manifestations in COVID19 may be an effect of microvascular occlusion due to hypercoaguable state consistent with the disease. Diverse clinical manifestations suggest lungs injury that results in respiratory problems in COVID-19 is not of classical ARDS pattern rather is associated with Membrane attack complex (C5b-9) deposition in pulmonary microvasculature inclining towards a potential complement mediated vascular injury resulting in coagulative vasculopathy [7]. We need prospective studies of treatment options and additional patient characteristics to further understand the variables associated with COVID-19-associated death in patients with this rare vasculopathy.

Conclusion

Inflammation is an essential part of an effective immune response. It is difficult to eliminate infections successfully without inflammation. SARS-CoV-2 induces excessive and

prolonged cytokine/chemokine responses in some infected individuals, known as the cytokine storm. Cytokine storm causes respiratory failure, compartmental syndrome or multiple-organ dysfunction, which leads to physiological deterioration and death. Timely control of the cytokine storm in its early stage through such means as immunomodulatory and cytokine antagonists, as well as the reduction of lung inflammatory cell infiltration, is the key to improving the treatment success rate and reducing the mortality rate of patients with COVID-19. We can hope to provide adequate clinical care and urgently design interventional studies to prevent Sars-Cov-2 infection in the patient with the novel vasculopathy because the mortality associated with this devastating pandemic is dramatically high.

References

1. Zhou P, Yang XL, Wang XG, Hu B, Zhang L, Zhang W, et al. A pneumonia outbreak associated with a new coronavirus of probable bat origin. *Nature*. 2020; 579: 270-273.
2. Ye Q, Wang B, Mao J. The pathogenesis and treatment of the 'Cytokine Storm' in COVID-19. *J Infection*. 2020; 80: 607-613.
3. Baig M, Khaleeq A, Usman A. Evidence of the COVID-19 virus targeting the CNS: tissue distribution, host - virus interaction, and proposed neurotropic mechanisms. *ACS Chem Neurosci*. 2020; 11: 995-998.
4. Mondal R, Lahiri D, Deb S. COVID-19: Are we dealing with a multisystem vasculopathy in disguise of a viral infection?. *J Thromb Thrombolysis*. 2020; 50: 567-579.
5. Varga Z, Flammer AJ, Steiger P. Endothelial cell infection and endotheliitis in COVID-19. *Lancet*. 2020; 395: 1417-1418.
6. Schett G, Sticherling M, Neurath MF. COVID-19: risk for cytokine targeting in chronic inflammatory diseases?. *Nat Rev Immunol*. 2020; 20: 271-272.
7. Conti P, Ronconi G, Caraffa A, Gallenga CE, Ross R, Frydas I, et al. Induction of pro-inflammatory cytokines (IL-1 and IL-6) and lung inflammation by coronavirus-19 (COVI-19 or SARS-CoV-2): anti-inflammatory strategies. *J Biol Regul Homeost Agents*. 2020; 34: 2.