



# Laparoscopic Management of Ovarian Torsion in Pregnancy in 1st Trimester - Case Report

Ponnusamy G\*

Specialist Gynaecologist DGO, DNB OG, MRCOG, Bachelor in Gynecological Endoscopy, UK

\*Corresponding author: Ponnusamy G, Specialist Gynaecologist DGO, DNB OG, MRCOG, Bachelor in Gynecological Endoscopy, UK; E-mail: [asgomathi@gmail.com](mailto:asgomathi@gmail.com)

## Abstract

Ovarian torsion in pregnancy is an obstetric emergency. Prompt diagnosis and management is essential to reduce maternal and fetal morbidity. I am discussing the case report of ovarian torsion presented in the early pregnancy and how it was managed laparoscopically.

**Keywords:** Ovarian; Obstetric emergency; Pregnancy; Gynaecology

## Introduction

The estimated incidence of ovarian torsion in pregnancy is 1-5 in 10000 pregnancies and may be as high as 16% in pregnant women with OHSS [1]. It can occur at any time in pregnancy, but is more common in the first and early second trimesters. It can occur without an adnexal mass (torsion of a normal-sized ovary) in pregnancy. Here I am going to discuss about a case presented with acute abdominal pain early pregnancy, work up revealed torsion of normal sized ovary.

## Case Report

A 26 yrs old g2p1, came to urgent care with acute right sided pain abdomen, she was 5 weeks 6 days pregnant, it was intrauterine pregnancy, no history of bleeding per vaginum, no history of fever, vomiting or loose stools. Clinical examination revealed moderately built lady, not pale, afebrile, abdomen examination revealed severe tenderness right iliac region which is not relieved with simple analgesics like paracetamol, local examination revealed no bleeding or abnormal vaginal discharge. Blood counts were sent and urgent ultrasound ordered, Haemoglobin was 11.6, White blood cell count was normal 8.2, C-reactive protein was normal, ultrasound revealed intrauterine sac 5 weeks 6 days fetus, right ovary bulky 5.3\*3.2 cms with fluid around the right ovary, with consent of the couple further confirmation done with MRI showing bulky ovary with hyperintense parenchymal edema and

periovarian free fluid suspicious twisting of right ovarian pedicle suggestive of ovarian torsion. Patient and husband counselled about the need for intervention and small risk of miscarriage which can happen because of the current associated condition, they understood and agreed the plan of care. With informed consent under General anaesthesia patient posted for laparoscopy and proceed. Pneumoperitoneum created with supraumbilical verres insertion, intraabdominal pressure created upto 12 mm hg, intraoperative right ovary along with the tube twisted twice and both are edematous and congested and detorsion done, congestion reduced and ovarian ligament plication done with 2-0 prolene sutures since the ovarian ligament was lax and lengthy, post-operative period was uneventful. Prophylactic antibiotics and prophylaxis against deep vein thrombosis given. Now she is 16 weeks pregnant, Ultrasound antenatal done at 12 weeks, Down syndrome screening(NT) scan normal, ovaries also normal, patient is asymptomatic and she is coming for regular antenatal check-up and she is now managed as any low risk pregnant woman.

## Discussion

The clinical presentation of adnexal torsion is similar in pregnant and non-pregnant women [2,3]. Acute abdominal pain is the most common symptom; there are similar rates of nausea, vomiting, abdominal tenderness and signs of peritoneal irritation in both groups. Nausea and vomiting may be present in up to 85% of

**Received date:** 07 August 2021; **Accepted date:** 11 August 2021; **Published date:** 15 August 2021

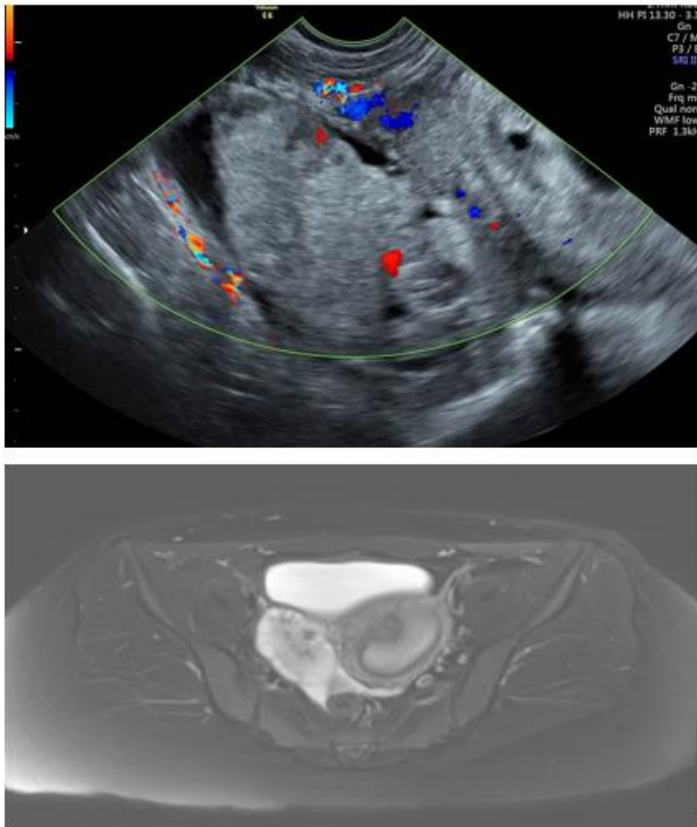
**Citation:** Ponnusamy G (2021). Laparoscopic Management of Ovarian Torsion in Pregnancy in 1st Trimester - Case Report. SunText Rev Surg 2(1): 116.

**DOI:** <https://doi.org/10.51737/2766-4767.2021.016>

**Copyright:** © 2021 Ponnusamy G. This is an open-access article distributed under the terms of the Creative Commons Attribution License, which permits unrestricted use, distribution, and reproduction in any medium, provided the original author and source are credited.

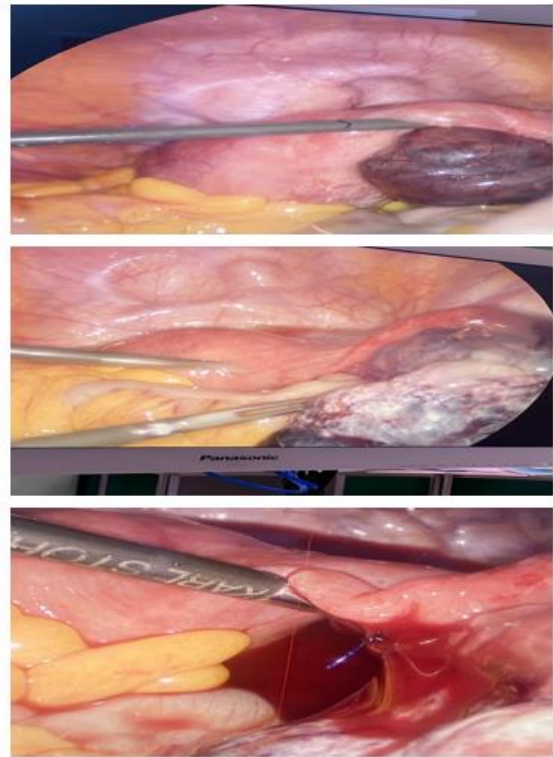
cases of ovarian torsion. However, pregnant women are more likely to present earlier following the onset of acute pain (Figures 1-3). They are twice as likely to have recurrent ovarian torsion compared to non-pregnant women [4]. White blood cell count in pregnant women is often mildly elevated, so this has little discriminatory power in diagnosis. C-reactive protein (CRP) is a nonspecific marker that is raised in most tissue injuries, including infarction, haemorrhage and infection. The CRP value starts to rise 6-8 hours after the onset of torsion and peaks at 24-72 hours. It has a very limited role in the early disease process, therefore clinical assessment and a high index of suspicion is important. Ultrasound can aid diagnosis by identifying a tender mass that has a thickened and oedematous capsule with a bland and often avascular centre.

obvious necrosis with no revascularisation after detorsion, unilateral salpingo-oophorectomy may be required.

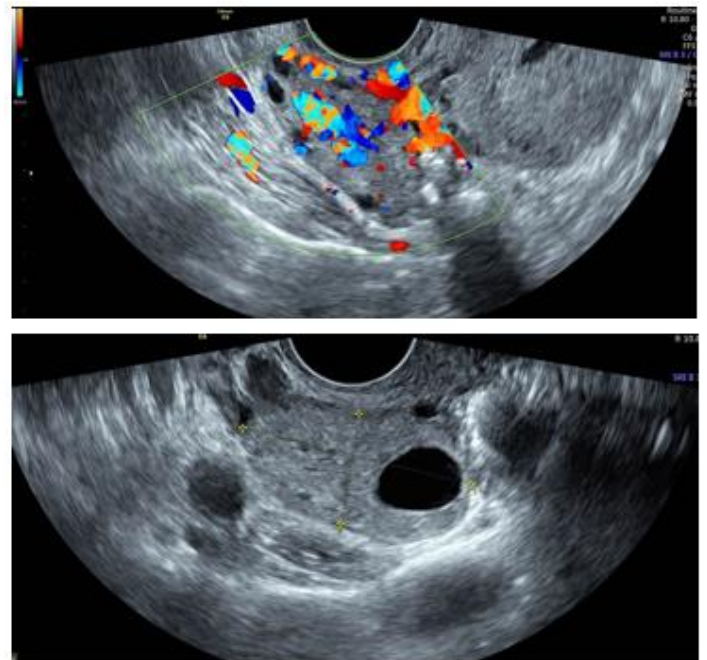


**Figure 1:** Preoperative images of ovarian torsion ovarian showing edema ovary with less vascularity-ultrasound and mri image.

Once a diagnosis is made then surgery should immediately follow; ideally, laparoscopy with adnexal detorsion, aspiration of an ovarian cyst, ovarian cystectomy or salpingo-oophorectomy. Prompt surgery allows adnexal detorsion to revascularise and preserve the ovary. Other surgical aims include reducing the size of the ovary to lower the risk of torsion recurrence. In many cases the ovary may be ischaemic, friable and oedematous, so the simple puncture and drainage of the ovarian cyst may suffice to treat acute pain with minimum risk to the pregnancy. In cases of



**Figure 2:** The operative images showing ovarian torsion, detorsion and ovarian plication.



**Figure 3:** Post op images showing normal ovary with good vascularity.

Diagnostic laparoscopy is safe and effective when used selectively in the workup and treatment of acute abdominal process in pregnancy. Laparoscopic treatment of acute abdominal

process has the same indication in pregnant and non-pregnant patients. Laparoscopy can be safely performed during any time in pregnancy. CO<sub>2</sub> insufflation pressure can be safely used upto 10-15 for adequate visualization of abdominal cavity. Intra operative CO<sub>2</sub> monitoring by Capnography should be used while operating in a pregnant patient. Intraoperative and post-operative thromboprophylaxis including pneumatic compression devices, low molecular weight heparin, early ambulation is indicated in these patients. Laparoscopy is recommended for diagnosis and treatment for the pregnant patient is suspected the possibility of adnexal torsion unless the clinical condition warrants laparotomy [5]. The maternal condition necessitating surgery may be associated with risk of miscarriage and preterm labour not due to procedure or anaesthesia per se [6]. Most studies have been reassuring and have concluded that a significant risk for congenital malformations is unlikely when surgery is performed during the first trimester [7,8]. For example, Mazze and Kallen described 5405 women from the Swedish Birth Registry who underwent non obstetric surgery during pregnancy, 40% of which occurred during the first trimester. They found no significant difference in the rate of congenital malformations compared with women who had no exposure to surgery during pregnancy. Furthermore, a more recent systematic review of the literature identified more than 12,000 pregnancies exposed to no obstetric surgery and reported an overall 2% incidence of congenital malformations, 3.9% when surgery occurred in the first trimester [9]. Maternal risk [6]: General laparoscopic surgical risks such as haemorrhage and herniation at the port site also apply to laparoscopy during pregnancy. Clinicians should be aware that there is increased risk of bleeding due to increased vascularity of uterus and adnexae, but this risk is currently not quantified.

## Conclusion

Torsion of normal ovary in pregnancy is a rare occurrence, it should be diagnosed and managed properly to reduce the maternal and fetal morbidity. Good maternal and fetal outcomes have also been reported for laparoscopic surgery for the first and third

trimester, however the number of reported cases is small. More research is needed to prove the superiority of one approach over the other outside the second trimester for the elective cases. In the interim, choice of approach should be decided based on local circumstances like this emergency cases and expertise.

## References

1. Alalade OA, Management of adnexal masses in pregnancy. 2017
2. Condous G, Khalid A, Okaro E, Bourne T. Should we be examining the ovaries in pregnancy? Prevalence and natural history of adnexal pathology detected at first-trimester sonography. *Ultrasound Obstet Gynecol.* 2004; 24: 62-66.
3. Ginath S, Shalev A, Keidar R, Kerner R, Condrea A, Golan A, et al. Differences between adnexal torsion in pregnant and nonpregnant women. *J Minim Invasive Gynecol.* 2012; 19: 708-714.
4. Hasson J, Tsafrir Z, Azem F, Bar-On S, Almog B, Mashiach R, et al. Comparison of adnexal torsion between pregnant and nonpregnant women. *Am J Obstet Gynecol.* 2010; 202: 1-6.
5. Schwartz N, Ludmir J. *Gabbe's Obstetrics: Normal and Problem Pregnancies, Society of American endoscopy and laparoscopic surgeon guidelines.* 2020; 31: 586-600.
6. Ball E, Waters N, Cooper N, Talati C, Mallick R, Rabas S, et al. Evidence-based guideline on laparoscopy in pregnancy. *Facts Views Vis Obgyn.* 2019; 11: 5-25.
7. Czeizel AE, Pataki T, Rockenbauer M. Reproductive outcome after exposure to surgery under anesthesia during pregnancy. *Arch Gynecol Obstet.* 1998; 261: 193-199.
8. Mazze RI, Kallen B. Reproductive outcome after anesthesia and operation during pregnancy: a registry study of 5405 cases. *Am J Obstet Gynecol.* 1989; 161: 1178-1185.
9. Kerem CR, Railton C, Oren D, Lishner M, Koren G. Pregnancy outcome following non-obstetric surgical intervention. *Am J Surg.* 2005; 190: 467-473.