



Dermoscopic Description of Scarring Alopecia after Scalp Irradiation

El Bennaye H*, Douhi Z, Baybay H, Soughi M, Elloudi S and Mernissi FZ

Department of Dermatology, University Hospital Hassan II, Fes, Morocco

*Corresponding author: El Bennaye H, Department of Dermatology, University Hospital Hassan II, Fes, Morocco, Tel: +212 661089847; E-mail: hajarelbennaye1@gmail.com

Abstract

We report the case of a 40-year-old diabetic patient on insulin. Followed since 2014 for a dermatofibrosarcoma of Darrier Ferrand operated four times and then received adjuvant radiotherapy on the scalp (total dose of 66Gy), under clinical monitoring.

Keywords: Leucotrichic hair; Coiled hair; Blackheads; Whiteheads; Pigmented areas

Introduction

One of the most troubling and depressing complication for patients who received radiation in the scalp for a tumour process is alopecia, which in some cases can be scarring and have a significant psychological impact on the patient's quality of life [1,2].

Case Presentation

We report the case of a 40-year-old diabetic patient on insulin. Followed since 2014 for a dermatofibrosarcoma of Darrier Ferrand operated four times and then received adjuvant radiotherapy on the scalp (total dose of 66Gy), under clinical monitoring. The patient presented after her radiotherapy sessions, a diffuse alopecia on the scalp and referred to us for management. On clinical examination, the patient was conscious and stable. Dermatological examination found a diffuse scarring alopecia of the vertex centered by an atrophic scar, the traction sign was negative on the entire scalp and the rest of the somatic examination was normal. Dermoscopic examination revealed a central scarring alopecia with peripheral fluffy and leucotrichic hair, coiled hair, blackheads, whiteheads and pigmented areas without structures.

Received date: 06 September 2023; **Accepted date:** 15 September 2023; **Published date:** 19 September 2023

Citation: El Bennaye H, Douhi Z, Baybay H, Soughi M, Elloudi S, Mernissi FZ (2023) Dermoscopic Description of Scarring Alopecia after Scalp Irradiation. SunText Rev Case Rep Image 4(7): 209.

DOI: <https://doi.org/10.51737/2766-4589.2023.109>

Copyright: © 2023 El Bennaye H, et al. This is an open-access article distributed under the terms of the Creative Commons Attribution License, which permits unrestricted use, distribution, and reproduction in any medium, provided the original author and source are credited.

Discussion

Hair loss, temporary or permanent, is one of the most stressful side effects for patients undergoing oncologic treatment. The true prevalence of permanent alopecia by radiation may be underestimated as many patients do not complain and accept it as the price of the treatment [3].

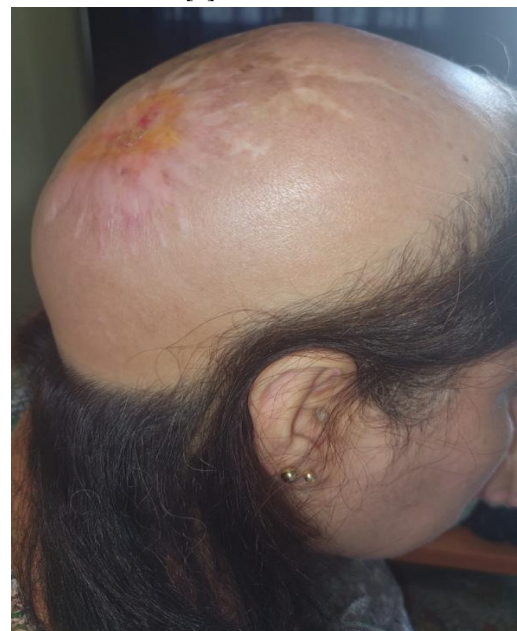

Figure 1: Clinical picture of scarring alopecia of the vertex centered by an atrophic scar.

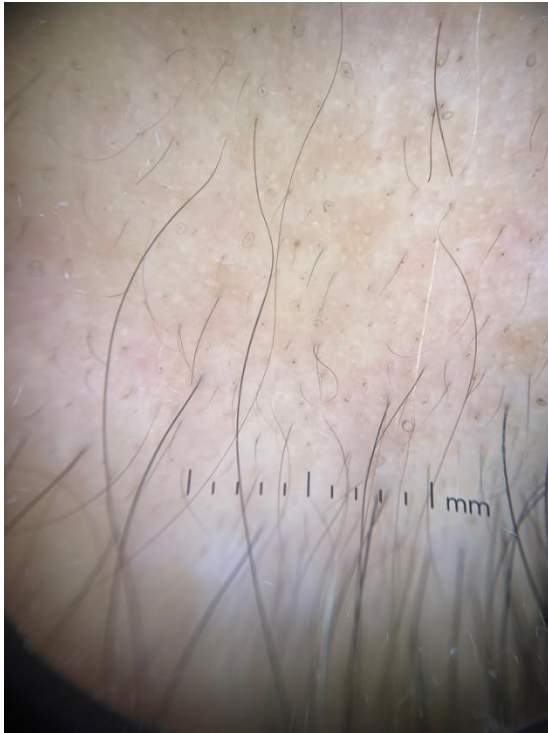

Figure 2: Dermoscopic image showing fluffy hair, coiled hair, leukotrich hair, white spots and pigmented areas without structures.

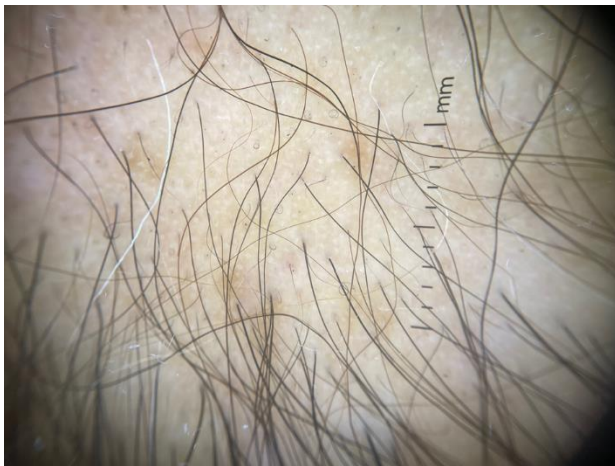


Figure 3: Dermoscopic image showing fluffy hair, coiled hair, leukotrich hair, white spots and pigmented areas without structures.

Permanent alopecia is a well-known side effect of radiation. Although the principal change following an acute dose of radiation is apoptosis, radiation damage can occur due to a combination of changes such as reduction in matrix cell reproduction, the effect on protein synthesis or plasma membrane permeability of matrix cells, and alteration in perifollicular blood flow [4]. Follicular dose (the dose of radiation at the level of hair follicle in a particular radiation field) is the only significant factor in determining the degree of permanent alopecia. Most anagen follicles are at a depth of 4 to 4.5 mm from the skin surface. If the

radiation superficial to this depth is kept under a lethal dose, the incidence of radiation-induced alopecia can be markedly reduced. The follicular dose at which 50% of patients develop permanent alopecia, is estimated to be 43 Gy [5] (Figures 1-3).

Conclusion

Dermoscopy of scarring alopecia following scalp irradiation has never been described. This is the first observation in the literature that describes this entity. Particular attention should be paid to this phenomenon in order to better characterize its specific dermoscopic signs.

Consent

The examination of the patient was conducted according to the Declaration of Helsinki principles.

Conflicts of Interest

The authors do not declare any conflict of interest.

References

1. Alley E, Green R, Schuchter L. Cutaneous toxicities of cancer therapy. *Curr Opin Oncol.* 2002; 14: 212-216.
2. Kiebert GM, Hanneke J, de Haes CJ, Kievit J, Van de Velde CJH. Effect of perioperative chemotherapy on the quality of life of patients with early breast cancer. *Eur J Cancer.* 1990; 26: 1038-1042.
3. Haider M, Hamadah I, Almutawa A. Radiation- and chemotherapy-induced permanent alopecia: case series. *J Cutan Med Surg.* 2013; 17: 55-61.
4. Malkinson FD, Keane JT. Radiobiology of the skin: review of some effects on epidermis and hair. *J Invest Dermatol.* 1981; 77: 133-138.
5. Lawenda BD, Gagne HM, Gierga DP, Niemierko A, Wong WM, Tarbell NJ, et al. Permanent alopecia after cranial irradiation: dose-response relationship. *Int J Radiat Oncol Biol Phys.* 2004; 60: 879-87.